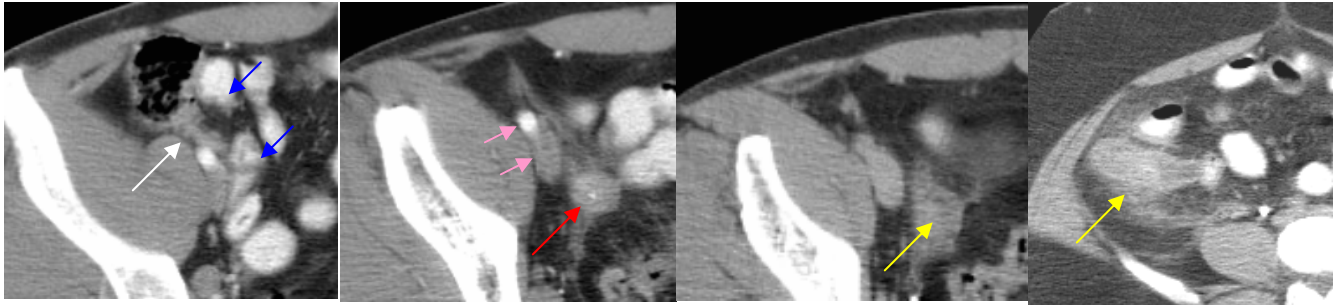




ADVANCED IMAGING CENTER
PHYSICIAN NEWS

March 14, 2005
www.aicValencia.com

Helical CT of the Appendix: State-of-the-art imaging of APPENDICITIS



Serial helical CT sections magnified through the right lower quadrant: Inflamed appendix (white arrow) between a loop of ileum (blue arrows) and the iliac vessels (pink arrows) with periappendiceal inflammation (yellow arrows) and a calcified appendicolith (red arrow).

CLINICAL INFORMATION: This patient presented to the primary care doctor with a few days of abdominal pain, particularly right lower quadrant pain. Appendicitis was suspected and a STAT helical CT of the appendix was requested.

HELICAL CT TECHNIQUE: At AIC, we usually obtain 3 helical sets (pre, post arterio-venous phase and delayed phase) on our multislice helical CT scanner. Rectal contrast is used to opacify the colon, particularly the cecum and appendix (if normal). Oral contrast is also given prior to the exam to opacify the small bowel. Each scan takes a breathhold. The entire procedure can be performed in a few minutes. If IV contrast is contraindicated, a non-contrast study may be adequate for the diagnosis. **Multiplanar reformations** is performed on our Advanced 3D Silicon Graphics Workstation to produce “BE-like” coronal and sagittal sections depicting the cecum and appendix in the RLQ.

HELICAL CT FINDINGS: The above images demonstrate a prominent tubular-shaped structure in the right lower quadrant with a 2 cm round tip containing a central calcification. The appendix can usually be located about 1 cm below the ileocecal valve arising from the medial aspect of the cecum. The above images also demonstrate periappendiceal stranding in the mesenteric fat due to inflammatory changes (phlegmon). A diagnosis of appendicitis was made based on the CT findings.

PATHOLOGIC CORRELATION: This is a surgically proven appendicitis.

CONCLUSION: If you have a patient with inconclusive clinical findings of appendicitis ... think MultiSlice Helical CT of the Appendix for definitive diagnosis!

For more information, or for any questions or concerns, please call me personally at (661) 255-0060.

Ray Hashemi, MD
Ray H. Hashemi, M.D., Ph.D.
Director