

**HIDA SCAN: VALUE OF HYBRID SPECT-CT FUSION**

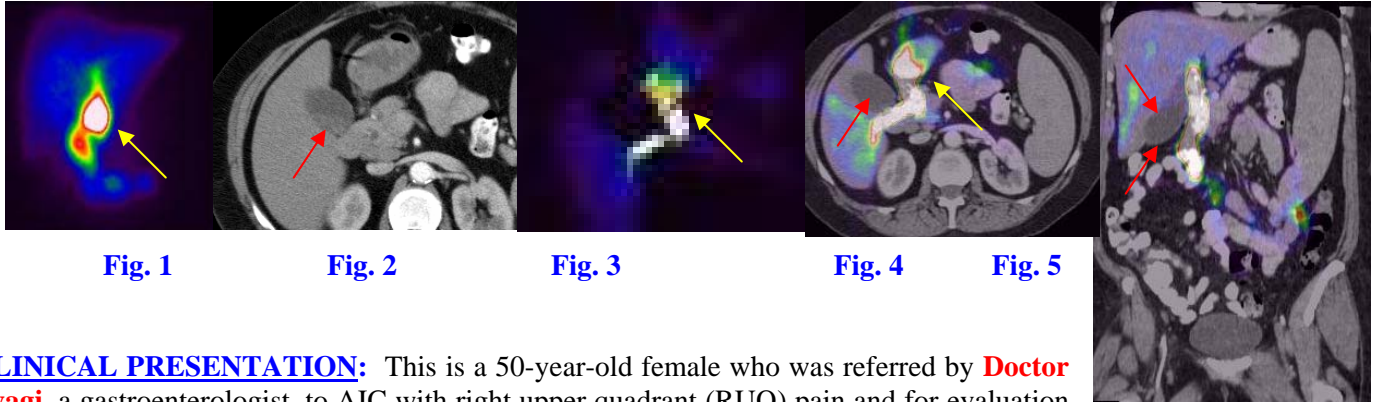


Fig. 1

Fig. 2

Fig. 3

Fig. 4

Fig. 5

**CLINICAL PRESENTATION:** This is a 50-year-old female who was referred by **Doctor Tyagi**, a gastroenterologist, to AIC with right upper quadrant (RUQ) pain and for evaluation of the gallbladder (GB). A CT was initially performed followed by a radionuclide hepatobiliary (HIDA) scan. Subsequently, SPECT images were performed and the CT and SPECT images were fused rendering a hybrid **SPECT-CT**.

**IMAGING FINDINGS:** **Fig. 1** is an AP planar HIDA scan view demonstrating activity in the bile duct, bowel and a distended structure (could not tell if it was the GB or stomach/duodenum) (**yellow** arrow). It was crucial to make that distinction because activity in the GB would indicate a normal scan, while lack of activity is abnormal. **Fig. 2** is an axial CT cut through the gallbladder demonstrating mildly dense stones (red arrow). **Fig. 3** is an axial SPECT image showing the distended structure seen in Fig. 1 (yellow arrow). **Fig. 4 & 5** are axial and coronal fused SPECT and CT images (basically a **hybrid** of CT and nuclear SPECT) showing the GB (**red** arrows) separate from the other structure (**yellow** arrow), which is medial to the GB and can be explained by reflux of the radiotracer into the antrum of the stomach on the hybrid images (**yellow** arrow). Red arrows = GB. Yellow arrows = Gastric antrum & duodenum.

**DIAGNOSIS:** The GB (gallbladder) was never visualized even on delayed images. The distended structure which was filled with the tracer and demonstrated emptying on delayed images corresponds to radiotracer reflux in the antrum of the stomach and not the GB. Based on this scan, a diagnosis of cholecystitis was rendered and the patient was admitted for cholecystectomy surgery, which revealed cholelithiasis and cholecystitis.

**DISCUSSION:** Without the SPECT and hybrid SPECT-CT, it would have been very difficult to rule in or out cholecystitis. Lack of GB visualization was diagnosed with 100% certainty on SPECT-CT images. SPECT stands for **S**ingle **P**hoton **E**mission **C**omputed **T**omography. SPECT images are tomographic images similar to CT or MRI slices, as opposed to conventional planar nuclear images (which are similar to x-ray images). SPECT is seldom used with HIDA scans, but this case proves the value of SPECT in indeterminate cases where one is unsure of GB visualization.

*Ray Hashemi, MD*  
Ray H. Hashemi, M.D., Ph.D.  
Director