

**CASE REPORT: ANOTHER CAUSE OF HIP PAIN**  
**(TORN LATERAL ROTATORS/QUADRATUS FEMORIS MUSCLE)**

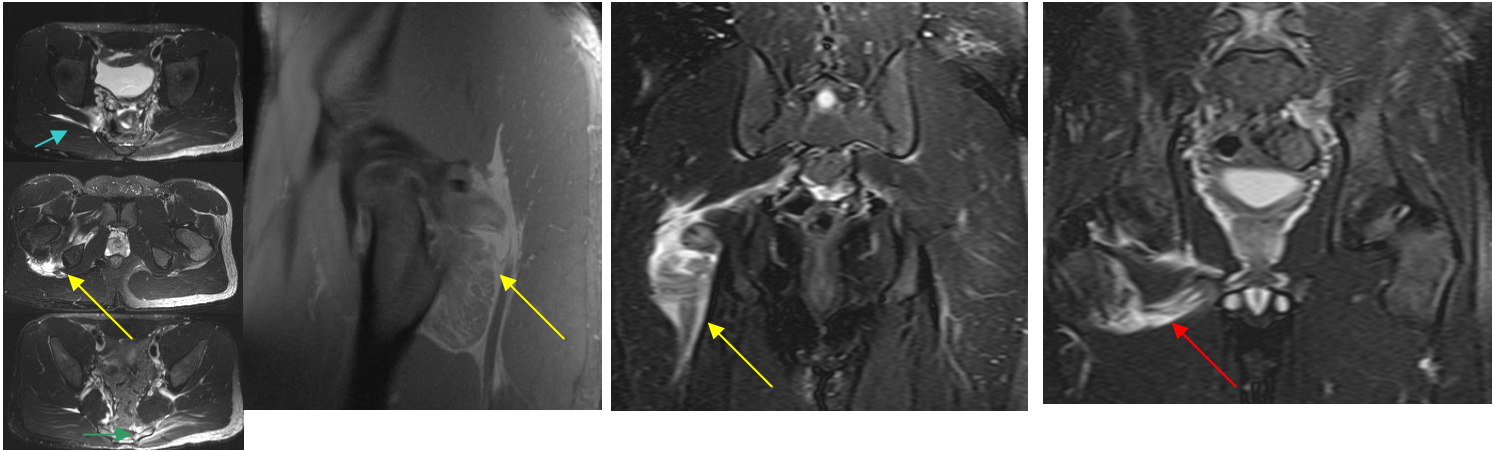


Fig. 1a,b,c

Fig. 2

Fig. 3

Fig. 4

**CLINICAL PRESENTATION:** This is a 20-year-old male who presented with right hip pain following a snowboarding trauma. An MRI of the Hips was performed at AIC as requested by **Dr. Ric Garrison, MD** and **Gigi Hammang, PA** from Garrison Family Medical Group in Palmdale, CA.

**ANATOMY:** **Yellow** arrows = quadratus femoris muscle; **blue** arrow = piriformis muscle; **red** arrow = obturator externus muscle; **green** arrow = gluteus maximus muscle. The hip has a complex soft tissue/muscle anatomy which include the following: *Anterior* thigh muscles (**iliopsoas, tensor fasciae latae, sartorius, and quadriceps femoris muscles**); *Gluteal* muscles (**gluteus maximus, medius, and minimus**); *Medial* compartment (**Adductors: pectineus, gracilis, and adductor magnus, brevis, and longus muscles**); *Posterior* compartment (**Hamstrings: semitendinosus, semimembranosus, and biceps femoris muscles**); and *Lateral Rotators* discussed below.

**FINDINGS:** MRI excluded any fractures. **Fig. 1a,b,c** are axial T2 weighted Fat Sat images demonstrating edema in the quadratus femoris and piriformis muscles and left gluteus maximus muscle. **Fig. 2 and 3** are sagittal proton density and coronal T2 weighted fat sat images, respectively, clearly showing a torn quadratus femoris muscle behind the femur. **Fig. 4** shows edema in and about the obturator externus muscle.

**DIAGNOSIS:** These findings are compatible with **TORN LATERAL ROTATOR MUSCLES** of the right hip. The most affected muscle is the quadratus femoris muscle which appears ruptured.

**DISCUSSION:** The lateral rotators of the hip include the quadratus femoris muscle (yellow arrows), piriformis muscle (blue arrow), obturator externus muscle (red arrow), and the superior and inferior gemelli muscles (not shown). They act to laterally rotate the extended thigh.

*Ray Hashemi, MD*  
Ray H. Hashemi, M.D., Ph.D.  
Director